

Examen clinique en cas de lombalgie aiguë



25.01.2012
Tatiana Sacroug
Raymond Dardel

1

Summary of recommendations for diagnosis of acute non-specific low back pain:

- Case history and brief examination should be carried out
- If history taking indicates possible serious spinal pathology or nerve rootsyndrome, carry out more extensive physical examination including neurologicalscreening when appropriate
- Undertake diagnostic triage at the first assessment as basis for managementdecisions
- Be aware of psychosocial factors, and review them in detail if there is noimprovement
- Diagnostic imaging tests (including X-rays, CT and MRI) are not routinelyindicated for non-specific low back pain
- Reassess those patients who are not resolving within a few weeks after the firstvisit, or those who are following a worsening course

www.backpaineurope.org

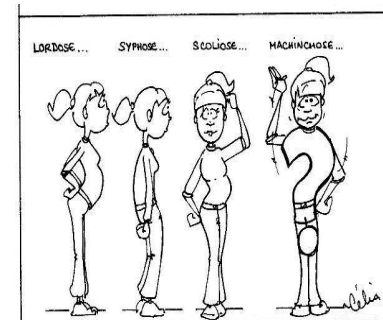
2

Red flags = signes d'alarme

- Trauma récent
- Age: < 20 ans, > 50 ans
- Douleur à caractère inflammatoire
- Co-morbidités (y.c. médicaments)
- Fièvre
- Affection cutanée
- Infection urinaire
- Déficit neurologique (y.c. troubles sphinctériens)
- Absence de syndrome lombo-vertébral

3

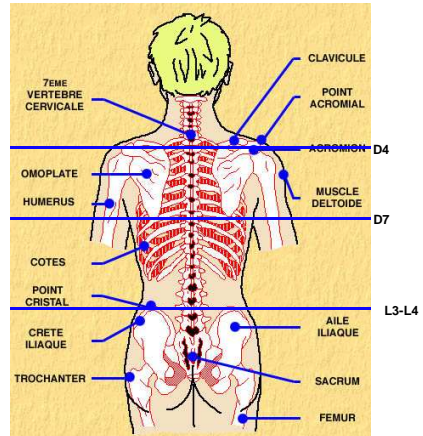
« ABC » de l'examen clinique



- Inspection
- Mobilisation
- Palpation
- Examen neurologique

4

Repaires anatomiques



5

Repaires anatomiques

- C6 - disparition en extension
- C7 – la plus facilement palpable
- D4 – angle sup-int. de l'omoplate
- D7 – angle inf. de l'omoplate
- L3-L4: ligne horizontale entre les sommets des crêtes iliaques
- Espace L5-S1: – ligne entre les SIPS

6

Inspection

- Démarche: boiterie, pied tombant
- Trouble statique: pseudo scoliose (« attitude de la baïonnette »)
- Inspection de la peau (psoriasis)

7

Mobilisation

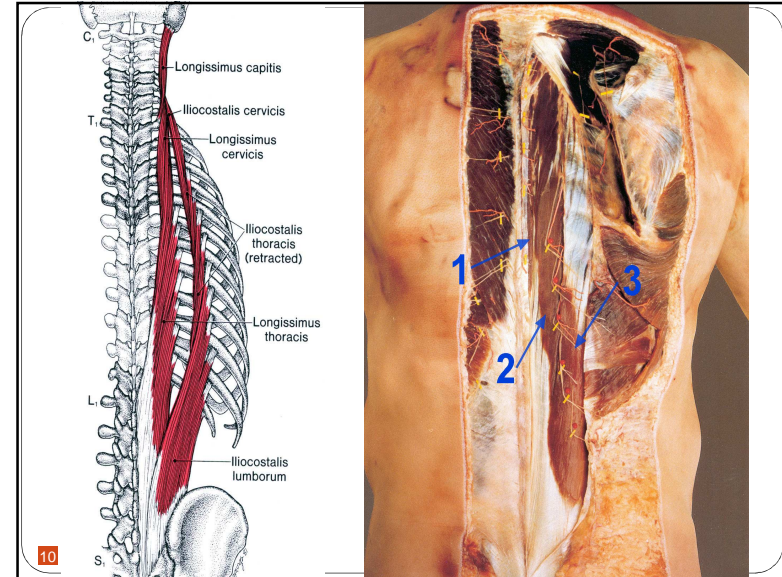
- Mouvements physiologiques
 - inclinaison latérale
 - flexion, DDS
 - extension
- Schober

8

Palpation

- Contracture musculaire
 - m. multifidii
 - m. longissimus
 - m. ilio-costalis
- M. psoas iliacus
- m. gluteus medius
- m. gluteus minimus
- m. piriformis
- m. quadratus lumborum

9



10

Examen neurologique

- Force debout/couché
- Sensibilité superficielle
- ROT
- Lasègue (SLR), Slump

11

Testing for lumbar nerve root compromise

Nerve root	L4	L5	S1
Pain			
Numbness			
Motor weakness	Extension of quadriceps	Dorsiflexion of great toe and foot	Plantar flexion of great toe and foot
Screening examination	Squat and rise	Heel walking	Walking on toes
Reflexes	Knee jerk diminished	None reliable	Ankle jerk diminished

Data from: Bigos, S, Bowyer, O, Braen, et al. Acute Low Back Problems in Adults. Clinical Practice Guidelines. Quick Reference Guide Number: 14. Rockville, MD: U.S. Department of Health and Human Services, Public Health Service, Agency for Health Care Policy and Research, AHCPR Pub. No. 95-0643, December 1994.

12

