Diagnostic approach for lung abnormalities in patients with hematologic diseases

or « La Pneumo-Hématologie »…

Anne Bergeron
Pneumologie
Hôpital Saint Louis, France

Position of the problem

- Frequent pulmonary involvement (> 50%)
- 40% deaths in this population of patients
- Various populations of patients

Vento, Lancet Oncol, 2008

Etiology of lung infiltrates

Infectious (50-75%)

- Bacteria
  - Community acquired
  - Nosocomial
  - Mycobacteria
- Fungi
  - *Pneumocystis jirovecii*
  - *Aspergillus*
  - Emerging
- Virus

…….

- Parasites
  - Toxoplasma
  - « Exotic »

Non infectious (25-50%)

- « Specific »
  - Lymphoma
  - Leucostasis
- Pulmonary edema
- Intra-alveolar haemorrhage (Thrombocytopenia)
- Drugs
- "Immunological"
  - Autoimmunity (myelodysplastic syndromes)
  - Graft versus host disease
  - Irradiation
- Malignancies
  - Secondary neoplasms
  - « random »
- Alveolar proteinosis

Male, 53 y
CML treated with Dasatinib 70 mg x 2/d
Since 1 year

Fever 39°C
Cough, dyspnea
Focal pulmonary crackles

Pleurocentesis:
2600 éléments : 96% lymphocytes

BAL : 400 000 c/ml
69% macrophages
25% lymphocytes
6% neutrophils

Negative extensive search for pathogens

Pneumonia and pleural effusion due to Dasatinib

Bergeron, Am J respir Crit Care Med, 2007

Female 60 y
2000: Diffuse lymphadenopathies: chronic lymphoid leukemia
2001: Guillain-Barré syndrome; Richter; Chemotherapy
2002: fever, increase of cervical adenopathies: lymph node tuberculosis
2008: Hemolytic anemia: Prednisone, IVIg
2009:Cough, sputum, no fever, loss of weight
Bone marrow biopsy: massive lymphoid infiltration of CLL

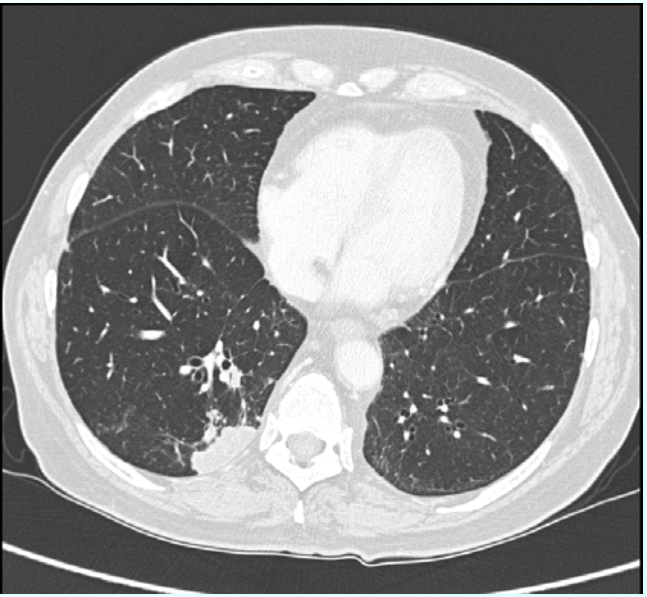

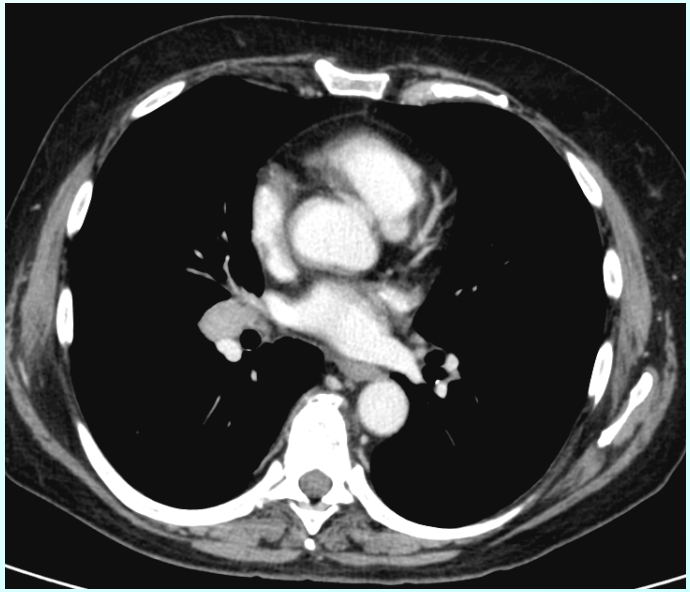

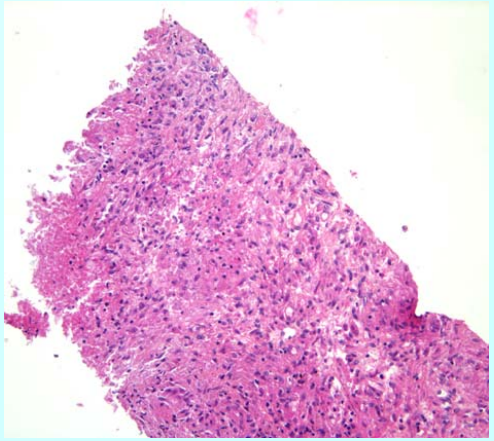

Infectious pneumonia

Underlying condition	Type of immunosuppression	Pathogens
• Chemotherapies	**Neutropenia/neutrophil dysfunction**	Bacteria, fungi
• Chronic lymphoid leukaemia, myeloma, primary immunodeficiency diseases, Allogeneic stem cell transplantation, anti-CD20 monoclonal Ab	**Deficiency in humoral immunity**	Encapsulated bacteria
•Immunosuppressants, anti-CD52 monoclonal Ab, antithymocyte globulin, purine analogs, long-term corticosteroid therapy, allogeneic stem cell transplantation, Hodgkin lymphoma, lymphoproliferative diseases	**Deficiency in cellular immunity**	Mycobacteria, *nocardia*, *légionella*, virus, fungi (*pneumocystis*, *cryptococcus, histoplasma, coccidioides immitis*), parasites (*toxoplasma gondii*)
• Splenectomy, splenic irradiation, total body irradiation	**Splenic dysfunction**	*Streptococcus pneumoniae*

Anti-TNF monoclonal antibody

Severe bacterial pneumonias
Curtis, CID, 2006

Legionellosis
Tubach, CID, 2006

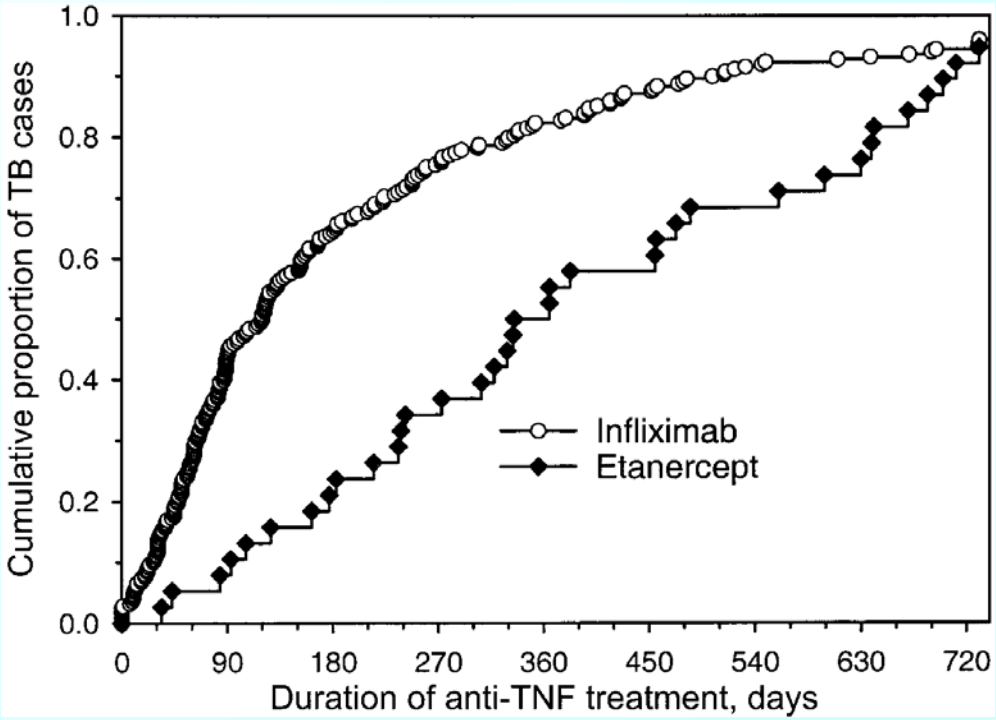

Wallis, CID, 2005

Complexity of immunosuppression

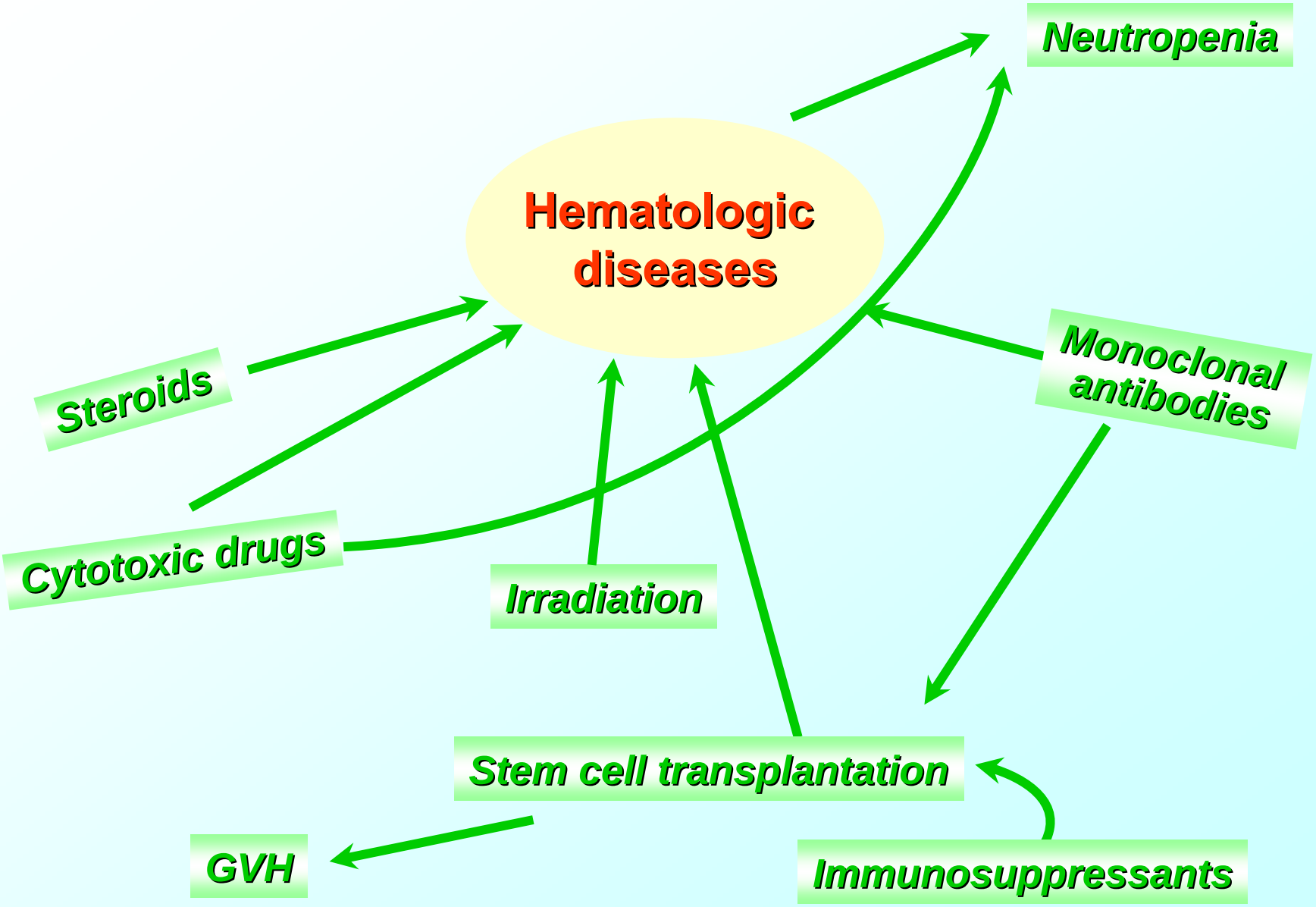

In the true life…

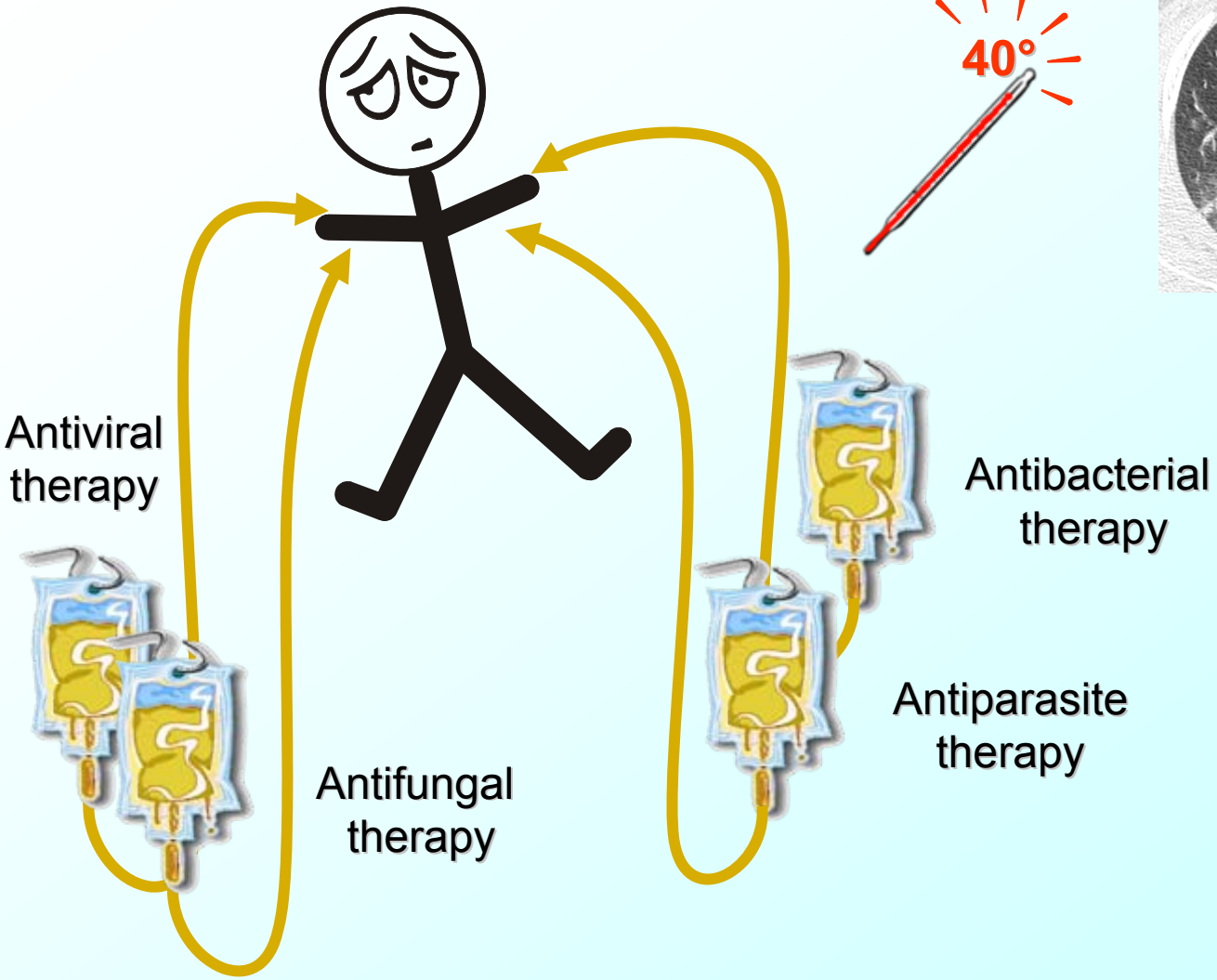

Is it necessary to specify the etiology of the pneumonia ?

Is it necessary to specify the etiology of the pneumonia ?

- Does it influence the prognosis?
  - Early investigation
- Impact on therapeutic decision?
  - Cost-effectiveness

Azoulay, Medicine, 2004
Von Eiff, Eur J Haematol, 1995
Rano, Chest, 2002
Rano, Thorax, 2001

Change in empirical therapy after lung investigations

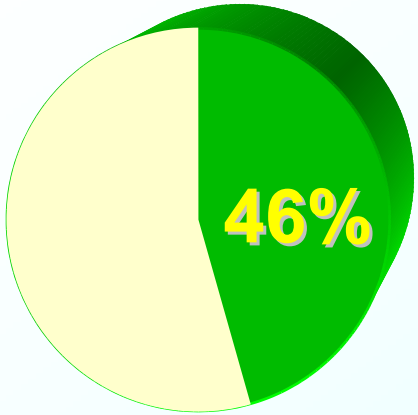

Rano, Thorax, 2001

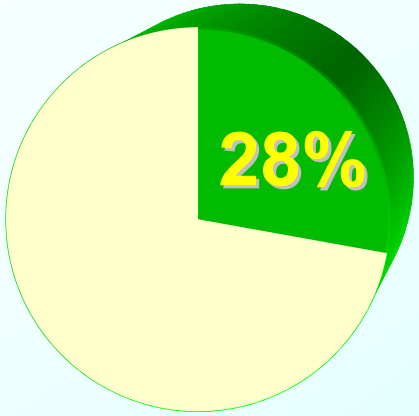

Gruson, Crit Care Med, 2000

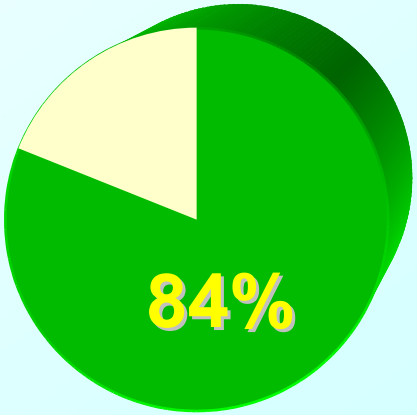

Hohenadel, Thorax, 2001

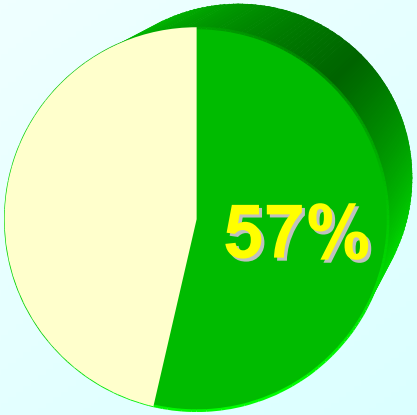

White, AJRCCM, 2000

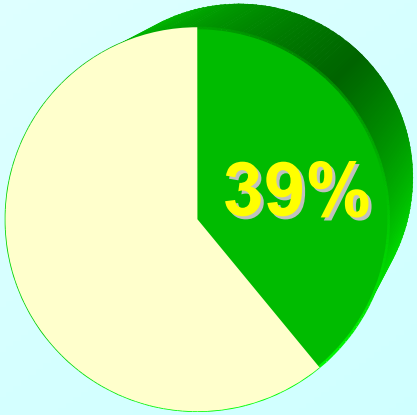

Hummel, Ann Hematol, 2007

Diagnostic approach for lung abnormalities in patients with hematologic diseases

Main issues to be considered in the diagnostic approach

Anamnesis	Clinical data	Biological diagnostic tools	Lung diagnostic tools
Profile of immunosuppression : • underlying disease • current and previous immunosuppressants • length and depth Administred antiinfectious therapy : • probability treatment • preventive treatment	History of symptoms Fever Cough, sputum, Chest pain, hemoptysis Lung examination Extrathoracic signs	Blood: culture, PCR, Ag, CRP, BNP Urine: Ag	Respiratory samples : •Sputum •Nasal aspirate • Bronchial aspirate •BAL Lung HRCT Lung biopsy

Diagnostic approach for lung infiltrates:

Diagnostic tools

Lung High Resolution Computed Tomography

Lung HRCT

- Sensitivity >> chest X-rays
- « pattern » turns toward
  - Anatomic area of involved lung
  - Range of etiologies
- Replace in clinical context and results of the other investigations
- Guides bronchoscopy

Airways

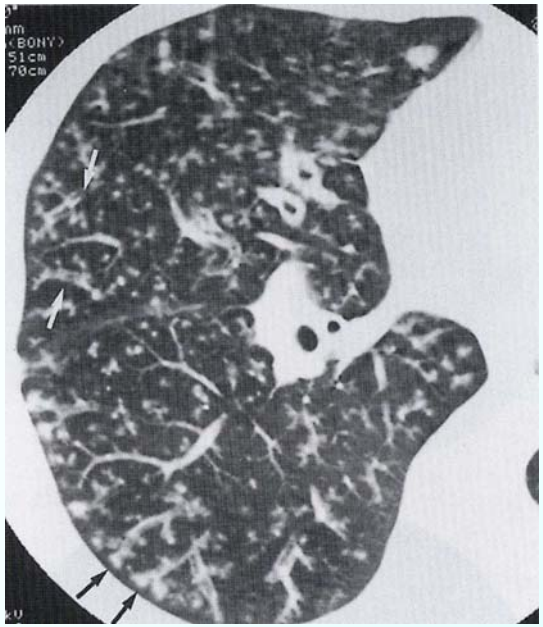

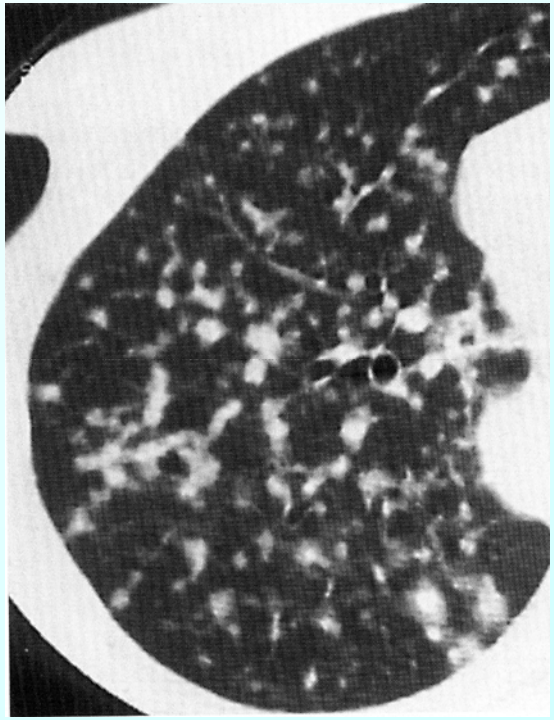

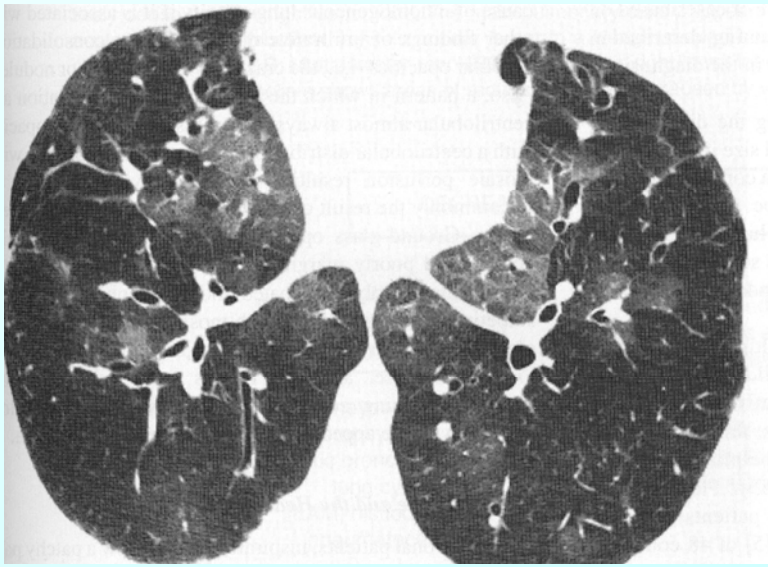

Virus
Fungi « airway-invasive »
Bacteria
Mycobacteria

Bronchiolitis obliterans

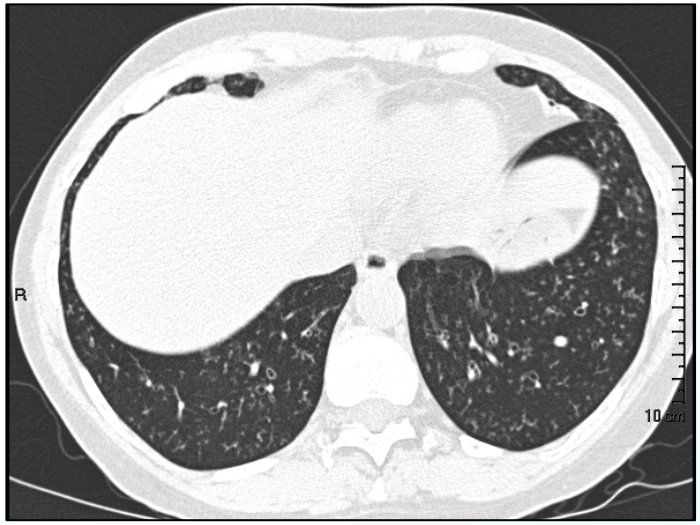

M12 Cord blood transplantation

***Parainfluenzae* bronchiolitis**

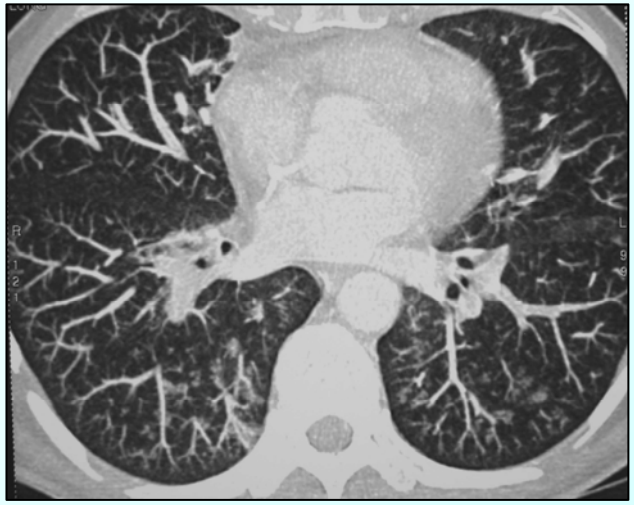

AL / MDS

***Aspergillus* bronchiolitis**

Induction AML

AraC bronchiolitis ***Chagnon, BJH, 2009***

Ground glass opacities

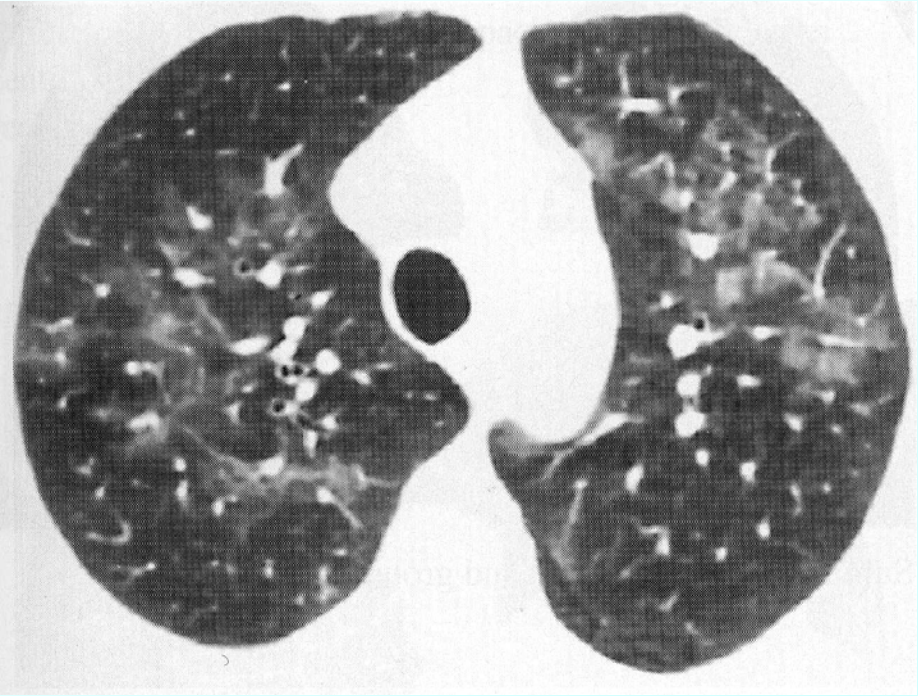

Pneumocystis pneumonia
Virus
Pulmonary edema
Hypersensibility (drugs)

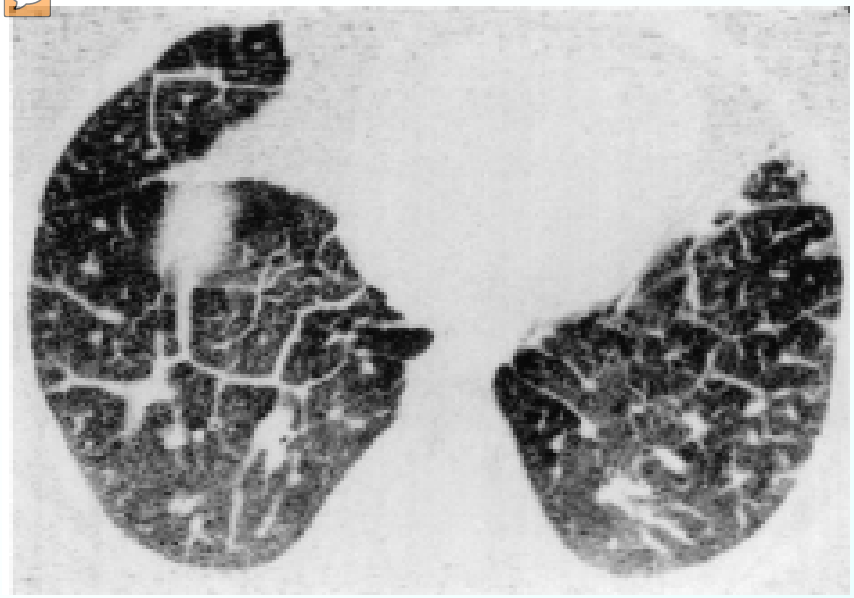

Septal thickening : lymphatic topography

Bronchiectasies, parenchymal distorsion:
Fibrotic process

Lung HRCT

- Combined lesions

And compatible clinical picture !..

Diagnostic tools

Bronchoscopy

Contribution of the bronchoscopy: BAL

- Good tolerance
- Diagnostic yield: 50%

- Heterogeneous populations of patients

Rano, Thorax 2001
Hohenadel, Thorax 2001
Bissinger, Diag Microbiol infect dis 2005
Hummel, Ann Hematol,2007
Kuehnhardt, Ann Hematol, 2009

53 AML / 68 lymphoid hemopathies

Diagnostic yield of BAL: AML

Diagnostic	Induction	Consolidation	After transplantation
14%	7%	50%	71%

Diagnostic yield of BAL

Neutropenic	Non neutropenic
11%	36%

Rabbat, Leukemia, 2008

BAL : contribution of the new microbiological tools

- Better sensitivity / Too much sensitivity?
  - Microbiological studies (few clinical correlations)
- Virus ++
- Fungi:
  - *Pneumocystis*: specificity et negative predictive value ++
    - » *Azoulay, Chest 2009*
    - » *Sing, J clin microbiol, 2000*
  - *Aspergillus* ?
- Bacteria?

Bronchoscopy: Transbronchial biopsies

- Evaluation in patients with hematologic diseases
  - ✓ Risks > benefits

White, Bone marrow transplantation, 1997

Patel NR, Chest, 2005

Hofmeister CC, Bone marrow transplantation, 2006

Lung biopsy

- surgical (thoracoscopy / open)
  - Diagnostic yield: 60%
  - Mortality/Morbidity

White, AJRCCM, 2000
Wang, Ann Thor Surg, 2004
Zihlif, Am J Hematol, 2005

- CT-guided
  - Few data
  - Suspected fungal disease (diagnostic yield 80%)

Hwang, AJR, 2000
Nosari, Haematologica, 2003
Lass-Flörl, Clin infect dis, 2007

CT-guided lung biopsy

Diagnoses for lung biopsies that yielded a specific result

Diagnosis	No. of biopsies (%) ($n = 130$)
Malignancy	83 (63.8)
Lymphoma	43 (33.1)
Adenocarcinoma of lung	15 (11.5)
Squamous cell carcinoma	14 (10.8)
Non-small cell carcinoma	7 (5.4)
Malignant fibrous histiocytoma	2 (1.5)
Atypical squamous metaplasia	1 (0.8)
Metastatic adenocarcinoma	1 (0.8)
Infectious	45 (34.6)
Aspergillus species	16 (12.3)
Mycobacterium species	5 (3.8)
Other fungal infections	11 (8.4)
Pneumocystis carini	2 (1.5)
Mixed fungal infection	3 (2.3)
Bacterial infection	5 (3.8)
Abscess	3 (2.3)
BOOP	2 (1.5)

Diagnostic yield for 213 patients: 60%

Diagnostic yield for 70 patients with previous negative bronchoscopy: 52.8%

Range of diagnosis **before** biopsy

Gupta, Hematol Oncol, 2009

Unresolved questions

- Is it necessary to refine the diagnostic approach for each population of hematologic patients?
- Would earlier investigations allow to improve the prognosis of these patients?
- How to optimize the diagnostic yield of bronchoscopy ?(evaluation of the new tools of molecular biology)

Does the investigation of the diagnostic accuracy of only one test have a real impact on clinical practice?

The example of
invasive pulmonary aspergillosis
(IPA)

Invasive pulmonary aspergillosis

Host factors

- Neutropenia
- Allogenic HSCT

- Corticosteroids ≥ 0.3 mg/kg/d prednisone eq for > 3 weeks
- T Immunosuppressants during the past 90 days:
  - Cyclosporine
  - Anti TNF Ab
  - Anti CD52 Ab
  - Nucleoside Analogues

Inherited severe immunodeficiency

Clinical criteria

- Lower respiratory tract fungal disease

Major:

- **Halo sign**
- Air-crescent sign
- Cavity within area of consolidation

Minor:

- Any new infiltrate not fulfilling major criterion
- Pleural effusion

Ascioglu, CID, 2002; De Pauw, CID, 2008

Diagnostic accuracy of lung HRCT for the diagnosis of IPA

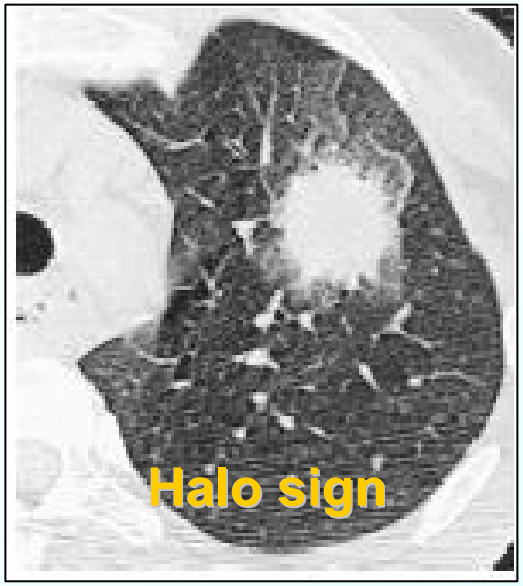

100 % 25 AL neutropenic

Caillot, J Clin Oncol 2001

***61%* 235 both neutropenic and non neutropenic**

Greene , CID, 2007

Imaging Findings in Acute Invasive Pulmonary Aspergillosis

Imaging findings in patients with invasive pulmonary aspergillosis.

Imaging finding	No. (%) of patients (N = 235)
Macronodule (≥1 cm in diameter)[a]	222 (94.5)
Halo sign[b]	143 (60.9)
Consolidation[c]	71 (30.2)
Macronodule, infarct shaped	63 (26.8)
Cavitary lesion[d]	48 (20.4)
Air bronchograms	37 (15.7)
Clusters of small nodules (<1 cm in diameter)	25 (10.6)
Pleural effusion	25 (10.6)
Air crescent sign	24 (10.2)
Nonspecific ground-glass opacification	21 (8.9)
Consolidation, infarct shaped	18 (7.7)
Small-airway lesions[e]	16 (6.8)
Atelectasis	7 (3.0)
Hilar/mediastinal lesion	4 (1.7)
Pericardial effusion	2 (0.9)

Greene , CID, 2007

List of diseases showing the CT halo sign

- Infectious diseases
  - Fungus; aspergillosis[a], mucormycosis, candidiasis, coccidioidomycosis, cryptococcosis
  - Septic embolism
  - Mycobacteria; tuberculosis, *Mycobacterium avium* complex
  - Rickettsia; *Coxiella burnetti*
  - Virus; herpes simplex virus, varicella-zoster virus, cytomegalovirus, myxovirus
- Neoplastic diseases
  - Primary tumours; squamous cell carcinoma, Kaposi sarcoma, bronchioloalveolar carcinoma[b], adenocarcinoma
  - Metastatic tumours; angiosarcoma, choriocarcinoma, osteosarcoma, melanoma, hydatidiform mole, metastatic tumours from gastrointestinal malignancies
  - Lymphoproliferative disorders
- Non-neoplastic, non-infectious, inflammatory diseases
  - Wegener's granulomatosis
  - Eosinophilic lung disease; parasitic infestation (schistosomiasis), simple pulmonary eosinophilia, hypereosinophilic syndrome
  - Pulmonary endometriosis
  - Organizing pneumonia
  - Hypersensitivity pneumonitis
  - Iatrogenic injury; transbronchial lung biopsy, catheter-induced pulmonary pseudoaneurysm

Specificity of halo sign?

Consider the prevalence of IPA in the populations of patients

Lee YR, British Journal of Radiology 2005

Invasive pulmonary aspergillosis

Host factors

- Neutropenia
- Allogenic HSCT

- Corticosteroids ≥ 0.3 mg/kg/d prednisone eq for > 3 weeks
- T Immunosuppressants during the past 90 days:
  - Cyclosporine
  - Anti TNF Ab
  - Anti CD52 Ab
  - Nucleoside Analogues

Inherited severe immunodeficiency

Clinical criteria

- Lower respiratory tract fungal disease

One of the following 3 signs on CT

- Dense, well-circumscribed lesions with or without a halo sign
- Air-crescent sign
- Cavity

- Tracheobronchitis
  - bronchoscopic analysis

Mycological criteria

- Direct tests

Sputum, BAL, bronchial brush

- Presence of fungal elements indicating a mold
- Recovery by culture of a mold

- Indirect tests

Serum, plasma, BAL
- GM Ag +

Serum
- β-D-glucan +

De Pauw, CID, 2008

Diagnostic accuracy of serum galactomannan

- Sensitivity: 79% (61-93%)
- Specificity: 82% (71-92%)

Leeflang, Cochrane Database of Systematic Reviews,2008

More and more….

- β-D glucan
- PCR
- MBL
- Gliotoxin……

- Serum
- BAL

Contribution of galactomannan antigen detection in BAL to the diagnosis of IPA

101 patients with hematologic malignancies

BAL for exploration of lung infiltrates

33 IPA

GM and Mycologic Results in Patients with IPA

	Proven (n = 6)	Probable (n = 23)	Possible (n = 4)	Total (n = 33)
BAL GM				
Positive ≥ 0.5	5	12	2	19
Negative < 0.5	1	11	2	14
Serum GM				
Positive ≥ 0.5	6	15	0	21
Negative < 0.5	0	8	4	12
Respiratory samples mycologic examination				
Positive direct examination	4	12	0	16
Negative direct examination	2	11	4	17
Positive culture	5	15	0	20
Negative culture	1	8	4	13
At least one positive criterion[a]	6	23	2	31

Bergeron, Chest, 2009

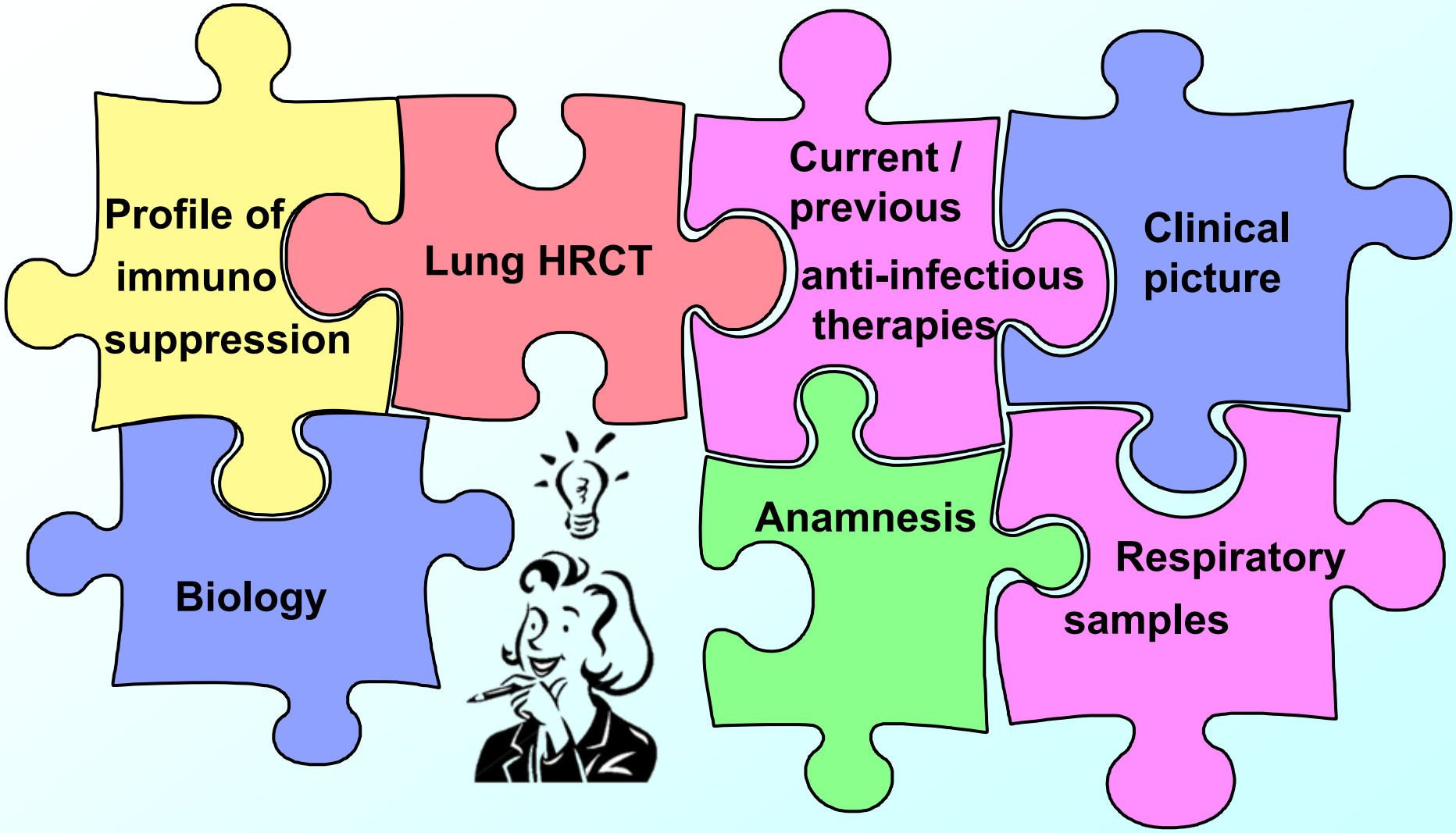
Profile of immuno suppression
Lung HRCT
Current / previous anti-infectious therapies
Clinical picture
Biology
Anamnesis
Respiratory samples

Case study

- 14 y,
- Geno-identical bone marrow transplantation for T ALL
- Previous sinusitis (surgery during ALL induction)
- Conditioning regimen: TBI + Cyclophosphamide
- GVHD prophylaxis : cyclosporine/methotrexate
- Fever during conditioning : Vancomycin, Imipenem, Ciprofloxacin, Amikacin
- D5 : Fever 39°C, bilateral pneumonia

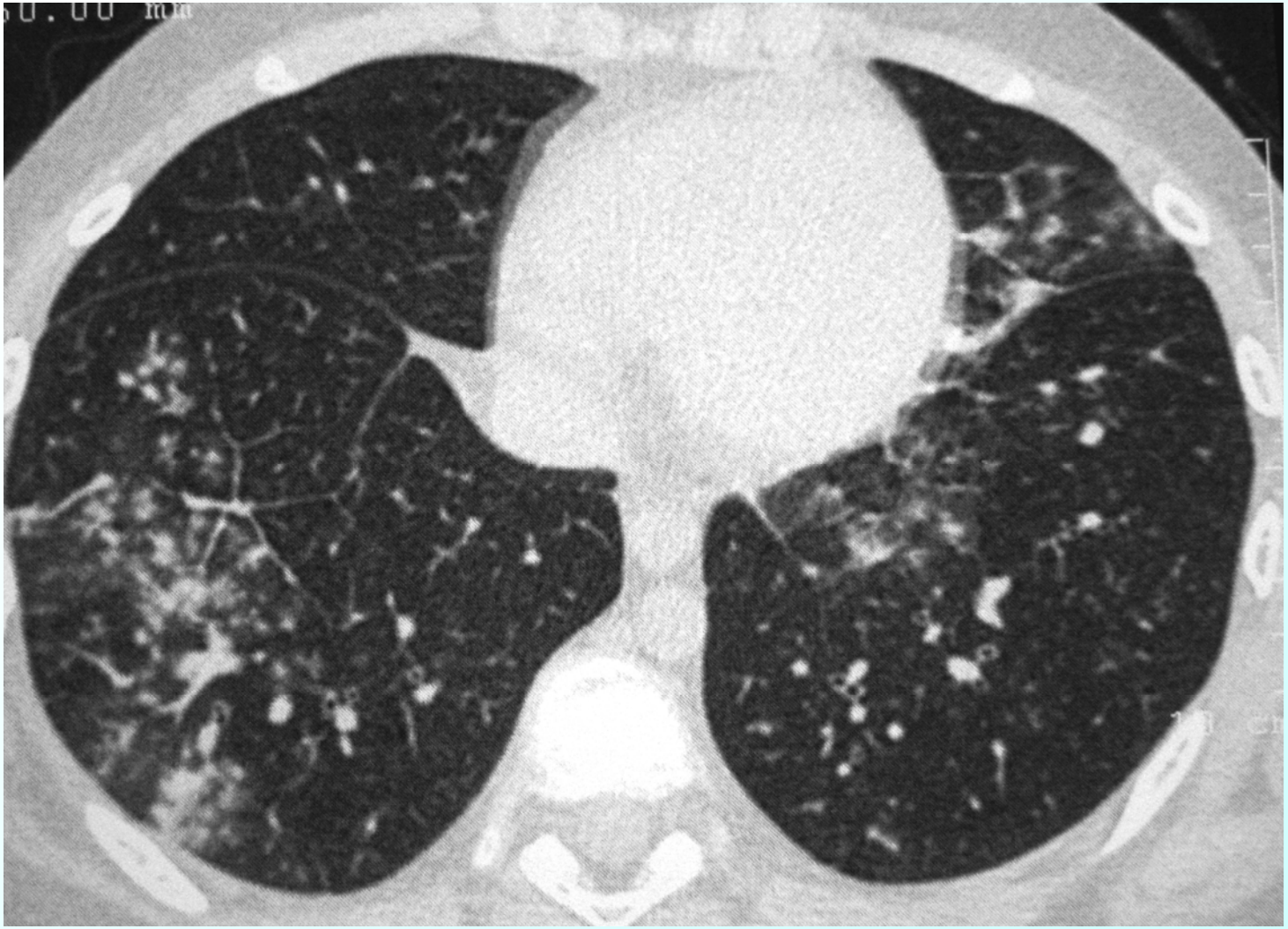

Airway dissemination : infection (bacteria, fungi, virus)

- BAL : negative extensive search for pathogens
- Worsening of lung condition: hypoxemia, dyspnea,
- Add new antimicrobial drugs : Vancocin, Imipenem, Ciprofloxacin, Acyclovir, Voriconazole
- Pneumonia still worsening, Fever 41°C
- Then trimethoprim-sulfamethoxazole, pyrimethamine, sulfadiazine….

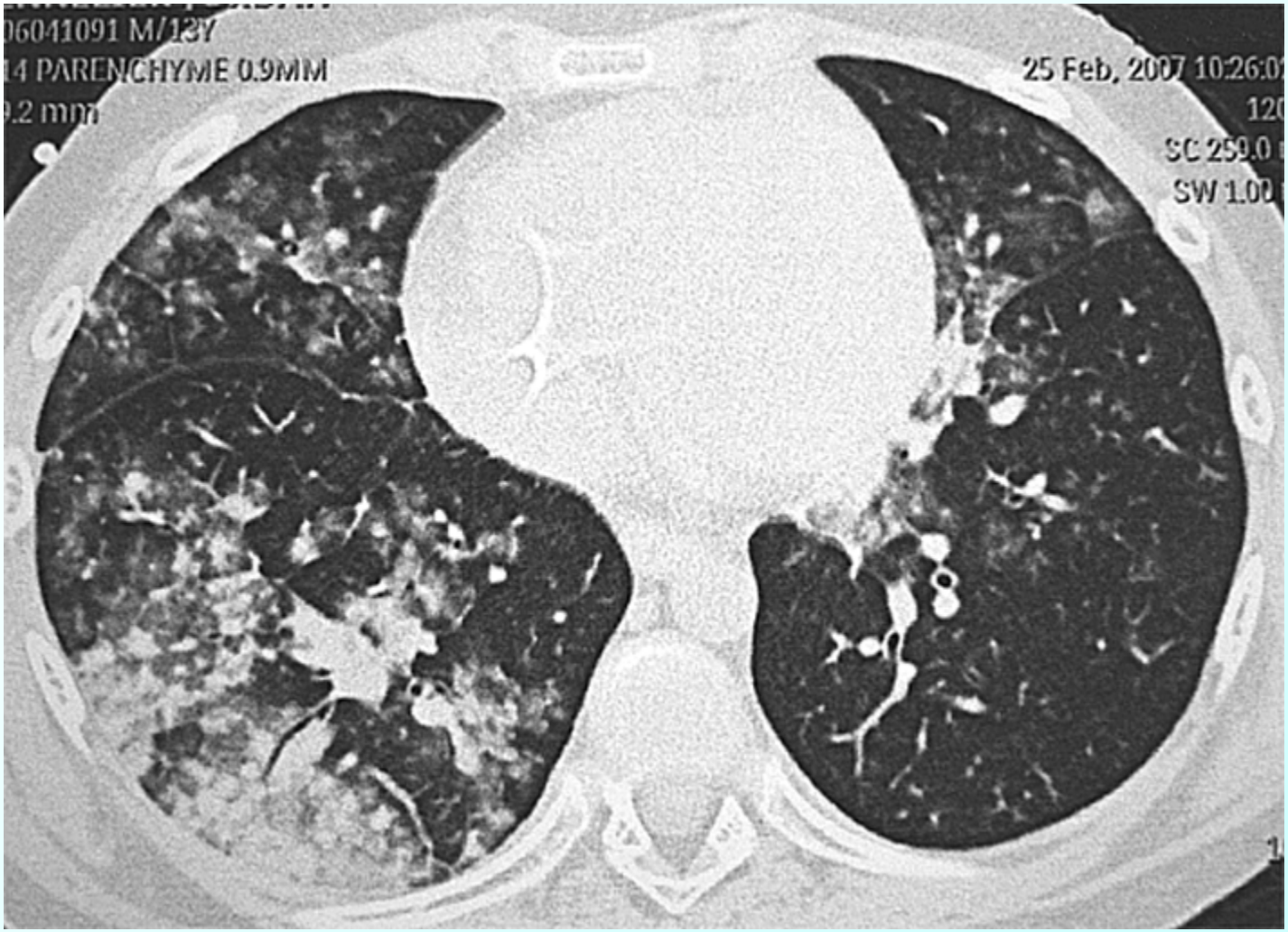
06041091 M/13Y
14 PARENCHYME 0.9MM
9.2 mm
25 Feb, 2007 10:26:0
120
SC 259.0
SW 1.00

Dry coughing fit

Features of the nodules on CT scan

Negative bronchial aspirate (fungi, bacteria)

Negative search for *RSV, Influenza, parainfluenza, adénovirus, CMV*

Failure of broad spectrum antimicrobiological empirical therapy

- D12 : 2nd BAL

Extensive search for other viruses

Metapneumovirus
Rhinovirus

Therapeutic de-escalation, successful outcome

Diagnostic approach for lung abnormalities in patients with hematologic diseases

The problem of the allogenic hematopoietic stem cell recipient in the late phase

Allogenic hematopoietic stem cell transplantation: Main lung complications at the late phase

Obliterans bronchiolitis
Organizing pneumonia

Diagnostic challenge

- M 64 y
- Refractory aplastic anemia
- Non-myeloablative, pheno-identical peripheral stem cell transplantation
- GVH skin, gut
- Tacrolimus, steroids, etanercept
- Posaconazole prophylaxis

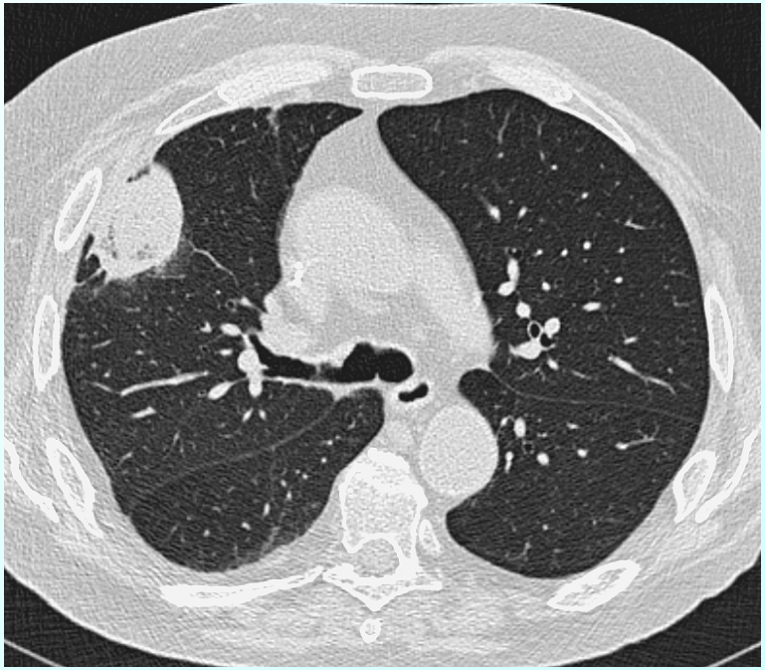

- **M9** : right chest pain
- Dry cough
- Hemoptysis

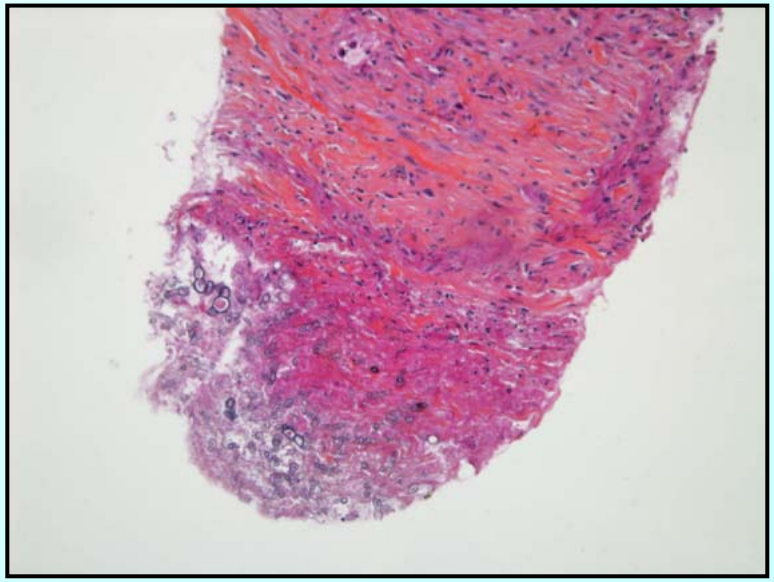

- Liposomal amphotericin B 10 mg/kg/d

3 weeks later…

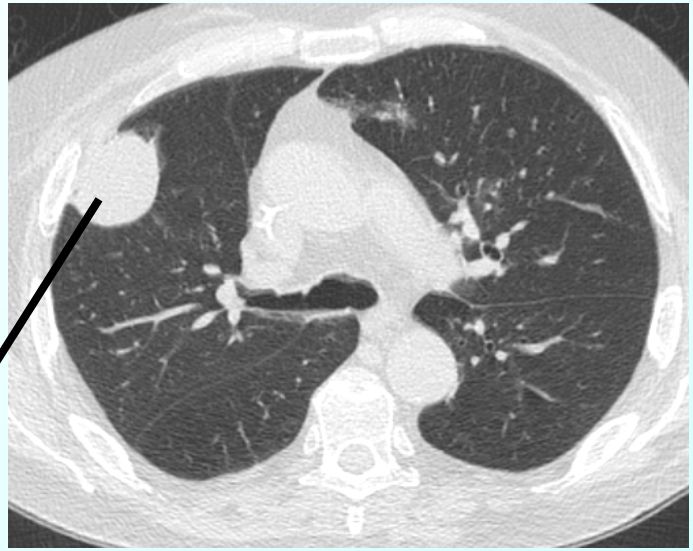



Mycobacterium tuberculosis

- F, 37 y
- Fanconi, myelodysplastic syndrome
- **M5** Cord blood transplantation
- Cyclosporine, hydrocortisone

- Left chest pain
- Fever 38°5°C
- Cough
- Dyspnea on exertion since 2 months

- Negative blood GM Ag
- BAL –
- CT-guided lung biopsy

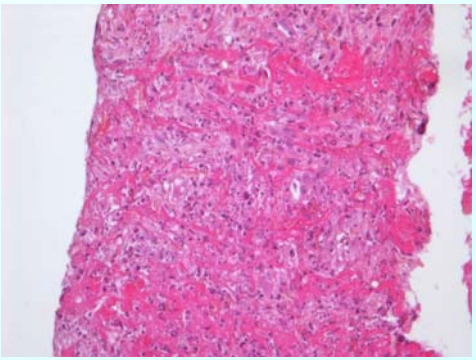

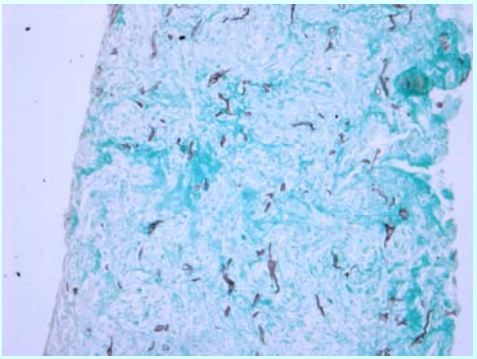

Hyphae associated with tissue damage

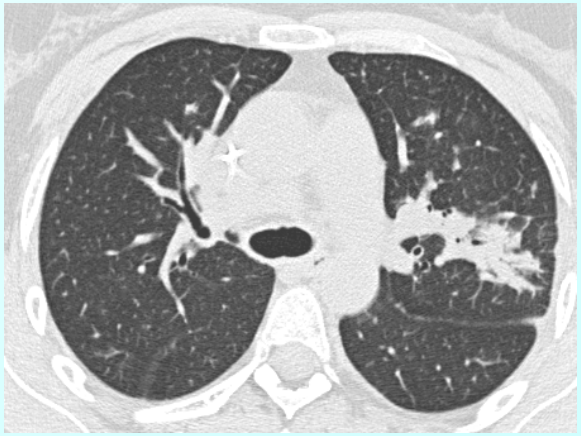

Antifungal treatment : liposomal amphotericin B

• W+3 : no fever, increased cough and dyspnea

Worsening of fungal pneumonia ?

- broad-spectrum antifungal treatment
- No more fever
- Few immunosuppresants

Hyphae corresponding to *Aspergillus*

- Dyspnea since 2 months
- Decrease immunosuppressants 2 months before

Organizing pneumonia

Pulse methylprednisolone therapy then prednisone 1 mg/kg/j

		M+1
Dyspnea	NYHA 4	NYHA 2
Oxygen saturation	92%	98%

In summary

- Consider ALL the elements
- Attentiveness of any moment
- Humbleness !