European Radiology (2019) 29:345–352
https://doi.org/10.1007/s00330-018-5573-1

EMERGENCY RADIOLOGY

Suspicion of appendicitis in pregnant women: emergency evaluation by sonography and low-dose CT with oral contrast

Pierre-Alexandre Poletti[1] · Diomidis Botsikas[1] · Minerva Becker[1] · Marlise Picarra[1] · Olivier T. Rutschmann[2] · Nicolas C. Buchs[3] · Habib Zaidi[1] · Alexandra Platon[1]

Received: 15 March 2018 / Revised: 7 May 2018 / Accepted: 29 May 2018 / Published online: 15 June 2018

Abstract

Objectives To evaluate non-intravenously enhanced low-dose computed tomography with oral contrast (LDCT) for the assessment of pregnant women with right lower quadrant pain, when magnetic resonance imaging (MRI) is not immediately available.

Methods One hundred and thirty-eight consecutive pregnant women with acute abdominal pain were admitted in our emergency centre. Thirty-seven (27%) of them, with clinical suspicion of acute appendicitis, underwent abdominal ultrasonography (US). No further examination was recommended when US was positive for appendicitis, negative with low clinical suspicion or showed an alternative diagnosis which explained the clinical presentation. All other patients underwent LDCT (<2.5 mSv). Standard intravenously enhanced CT or MRI was performed when LDCT was indeterminate.

Results Eight (22%) of 37 US exams were reported normal, 25 (67%) indeterminate, 1 (3%) positive for appendicitis, 3 (8%) positive for an alternative diagnosis. LDCT was obtained in 29 (78%) patients. It was reported positive for appendicitis in 9 (31%), for alternative diagnosis in 2 (7%), normal in 13 (45%) and indeterminate in 5 (17%). Further imaging (standard CT or MRI) showed appendicitis in 2 of these 5 patients, was truly negative in 1, indeterminate in 1 and falsely positive in 1. An appendicitis was confirmed at surgery in 12 (32%) of the 37 patients. The sensitivity and the specificity of the algorithm for appendicitis were 100% (12/12) and 92% (23/25), respectively.

Conclusions The proposed algorithm is very sensitive and specific for detection of acute appendicitis in pregnant women; it reduces the need of standard CTs when MRI is not available as second-line imaging.

Key points

- *In pregnant women, US is limited by an important number of indeterminate results*
- *Low-dose CT can be used after an inconclusive US for the diagnosis of appendicitis in pregnant women*
- *An algorithm integrating US and low-dose CT is highly sensitive and specific for appendicitis in pregnant women*

Keywords Appendicitis · Pregnant women · Tomography, X-ray computed · Radiation dosage · Emergencies

Introduction

Imaging plays a crucial role in the management of pregnant patients with right lower quadrant pain because this patient population is less likely to have a classic clinical and biological presentation of appendicitis, especially in the late pregnancy [1–4]. Obtaining a rapid diagnosis of appendicitis is important in pregnant women since the rate of fetal mortality dramatically increases (up to 30 %) in case of peritonitis or perforation, when compared to uncomplicated appendicitis (<4%) [3, 5, 6]. Ultrasonography (US) is universally accepted as the first line imaging to be performed in a pregnant woman with right lower quadrant pain [7–11]. Unfortunately, US is often inconclusive with pregnant women [12–17]. In this situation, there is no unanimously recognised guideline for the second line radiological tool that should be obtained [9, 18]. The European Society of Urogenital Radiology (ESUR) and the American College of Radiology (ACR) recommend to

✉ Pierre-Alexandre Poletti
pierre-alexandre.poletti@hcuge.ch

[1] Department of Radiology, University Hospital of Geneva, 4 rue Gabrielle-Perret-Gentil, 1205 Geneva, Switzerland

[2] Department of Community, Primary Care and Emergency Medicine, University Hospital of Geneva, Geneva, Switzerland

[3] Department of Surgery, University Hospital of Geneva, Geneva, Switzerland

perform magnetic resonance imaging (MRI) after indeterminate US, and to only use computed tomography (CT) when MRI is not available. However, they did not give any recommendation with regard to the CT protocols [7, 19], which raises concerns with regard to the dose of radiation to the fetus [14, 20]. Despite no deterministic risk being considered for the fetus at a dose <50 mGy [21], the threshold for the stochastic risk of cancer induction has been reported as low as 5 mSv [7]. The current study aims to evaluate whether a new diagnostic algorithm integrating US and ultra-low-dose CT with oral contrast media (LDCT), delivering a dose of radiation <2.5 mSv, is sufficient for the evaluation of pregnant women admitted with right lower quadrant pain, not suspected of a gynaecological condition.

Materials and methods

All consecutive adult (≥18 years) pregnant patients with suspicion of appendicitis admitted in our emergency centre during a 6 years period of time (1 January 2011 to 31 December 2016) were retrospectively included in this survey. This survey received approval of the local research ethics committee (IRB 2016-01-470), who waived written informed consent.

Pregnant women admitted with non-traumatic acute abdominal pain were initially investigated in a gynaeco-obstetrical emergency unit. If the cause of the pain was considered of gynaecological or obstetrical origin, patients were managed at the women's hospital. All other patients were transferred to our emergency service for further investigation and to undergo a complete transparietal abdominal US with a sectorial probe, by the radiologist on call, followed by a targeted right lower quadrant evaluation with a linear probe. Immediately after US examination, the radiologist reported his/her findings on a standardised electronic form, containing the list of the direct and indirect signs of appendicitis, as detailed in a prior series from the same institution [22]. This form also mentioned the clinical suspicion of the emergency physician for appendicitis, as transmitted to the radiologist, reported at low, intermediate or high, based on the clinical examination, the blood and urinary tests.

US was only considered positive when an enlarged (≥7 mm) incompressible appendix was clearly visualised, and negative when the appendix was visualised as normal, in the absence of indirect sign of appendicitis. Any other situation was reported indeterminate for appendicitis. Based on a guideline for pregnant women in force in our institution since January 2011, no further imaging was recommended for the diagnosis of appendicitis in the three following situations:

1. US reported positive for appendicitis
2. US reported negative for appendicitis in the presence of low clinical suspicion
3. An alternative diagnosis was reported by US, which explained the clinical presentation

In all other situations, LDCT was systematically performed after US. Indeed, in our institution, MRI is not used as second-line imaging, because it is not immediately available at the patient's admission.

LDCT

LDCT was interpreted by the attending radiologist on call. Based on previously reported LDCT signs for appendicitis [22], the radiologist had to consider the examination as positive, negative or indeterminate for appendicitis and for the presence of an alternative diagnosis. After completion of LDCT, the decision of performing further examination (standard CT or MRI) was let at the clinician's discretion, based on the re-evaluation of the clinical situation.

Technical imaging parameters

Ultrasound imaging

US was performed transabdominally using a Philips IU 22 device (Philips Healthcare, Best, Netherlands) with a sectorial 3.5- to 5-MHz probe for the assessment of intraperitoneal and retroperitoneal structures, and with a 12-MHz linear probe, for the assessment of the right lower quadrant.

CT imaging

Four hundred millilitres of oral contrast material (Telebrix-Gastro; Guerbet, Villepinte, France) were administrated 120 min before CT scanning to get an optimal opacification of the cecum [22, 23], while taking into consideration the reduced bowel mobility during pregnancy [24]. All CTs were performed on a 64-row GE 750 HD CT scanner (GE Healthcare, Little Chalfont, UK) from the lung base to the pelvis.

The LDCT protocol was set up to deliver a fixed $CTDI_{vol}$ of 2.5 mGy to a 32-cm body phantom [25] using the following parameters: 64 × 1.25mm collimation, 1.375 pitch, 0.7-s gantry rotation period, 120 kV tube potential, 31.5 mAs tube current corresponding to 22.9 effective mAs, i.e. mAs/pitch), 2.5 mm reconstruction slice thickness. A 40% iterative reconstruction algorithm blended with filtered back projection (LDCT-IR-FBP) was selected on a 10-100% strength scale, since it has been reported to provide both optimal noise reduction and a diagnostically acceptable image quality [26, 27].

Standard dose CT was performed on the same scanner used for LDCT from the lung base to the pelvis using a power-injected bolus of 120 ml of non-ionic intravenous contrast material (Iohexol, 300mg I/ml; Accupaque^R 300; GE Healthcare), at a flow rate of 3.5 ml/s, with a delay of 60 s

before initiating CT data acquisition, followed by a 30-ml saline flush at the same flow rate. The following parameters were used for CT acquisition: 64 × 1.25mm collimation, 0.9 pitch, 0.7-s gantry rotation period, 120 kV tube potential, automated tube current modulation, 2-1 mm acquisition thickness, 2-1 mm reconstruction slice thickness.

MRI was performed on the entire abdomen without intravenous contrast medium on two 1.5-T MRI scanners, Aera 1.5 T (Siemens Healthineers, Erlangen, Germany), or Ingenia 1.5 T (Philips Healthcare) with 20 s breath-hold (suspended end expiration). The protocol consisted of ultrafast T2 sequences, half-Fourier acquisition single shot turbo spin echo (HASTE®; Siemens Healthineers) or single-shot turbo spin echo (SSH-TSE®; Philips Healthcare) respectively on coronal and axial planes, along with the same sequences with fat saturation in the same planes.

Effective dose calculation

Clinical CT images were imported into Radimetrics™ dose tracking software [28] for calculation of maternal effective dose as well as the absorbed dose to the fetus [29].

The effective doses for pregnant patients estimated using Radimetrics varied between 1.7 and 2.3 mSv, with an average of 1.9 ± 0.14 mSv. The effective doses calculated using the dose-length products (DLP) and corresponding conversion factors of Huda et al. [30] ranged between 1.5 mSv and 1.9 mSv with an average of 1.6 ± 0.11 mSv. The radiation dose to the fetal body from CT examinations of pregnant patients varied within the range 6.7-13 mGy/100 mAs with a mean value of 9.2 mGy/100 mAs. As such, the fetal body dose was 2.47 ± 0.42 mGy.

Reference standard

For patients who underwent surgery, the definite diagnosis (reference standard) was obtained from the operating report and the histopathological analysis. For the other patients, this diagnosis was based on the discharge summary and on the consultation of their gynaecological file, until delivery. For patients who were further managed outside our institution, the information was obtained by phone call to their obstetrician 8 weeks after discharge.

Statistical analysis

Each step of the diagnostic algorithm was compared with the reference standard to determine the sensitivity and the specificity of the whole algorithm for the diagnosis of appendicitis. Once the imaging work-up was completed, MRI or standard CT examinations which remained indeterminate were considered as false-negative test results for the calculation of sensitivity and as false-positive test results for the calculation of specificity: doing so will result in conservative estimates, which compromise both sensitivity and specificity. A p value lower than 0.05 was considered statistically significant.

The statistical calculations were performed using QuickCalc for Windows (GraphPad Software, La Jolla, CA, USA).

Results

Study population

A total of 138 consecutive pregnant women, from 18 to 46 years old (mean, 32 years), with acute abdominal pain, in whom a gynaecological examination was normal, were admitted to our emergency centre during the study period. Thirty-seven (27%) of them, from 20 to 44 years (mean, 33), had a clinical suspicion of appendicitis and formed our study population. The remaining 101 patients with acute abdominal pain not clinically suspected of appendicitis did not meet our inclusion criteria and were therefore not considered as part of our study population. A diagnosis of appendicitis was found in only one (0.99%) of these 101 patients without initial clinical suspicion of appendicitis. This patient underwent an admission abdominal US for suspicion of cholecystitis, but she did not undergo a targeted US examination of the right lower quadrant. She underwent an LDCT, which eventually showed appendicitis.

Of the 37 women admitted with a clinical suspicion of appendicitis, 11 (30%) were at the first trimester of pregnancy (6-11 weeks), 14 (38%) at the second trimester (12-23 weeks) and 12 (32%) at the last trimester (26-35 weeks).

The clinical suspicion of appendicitis was considered low in 7 patients (19%), high/moderate in 30 (81%).

A diagnosis of appendicitis was confirmed at surgery in 12 (32%) of these 37 patients. One of them was a periappendicitis associated to a septic abortion, in a 10-weeks pregnant patient, who lost her fetus.

Algorithm diagnostic performance

Figure 1 shows the radiological management of the 37 pregnant patients with a clinical suspicion of appendicitis, following our institutional algorithm.

US results

The diagnosis of appendicitis was done by US in one patient (second trimester) (Fig. 2), who underwent surgery without further imaging. The diagnosis was confirmed at pathological analysis of the specimen.

US was reported negative in 11 patients. An alternative diagnosis was reported in three of them: one (first trimester) had a complicated uterine fibroma and two (both at second

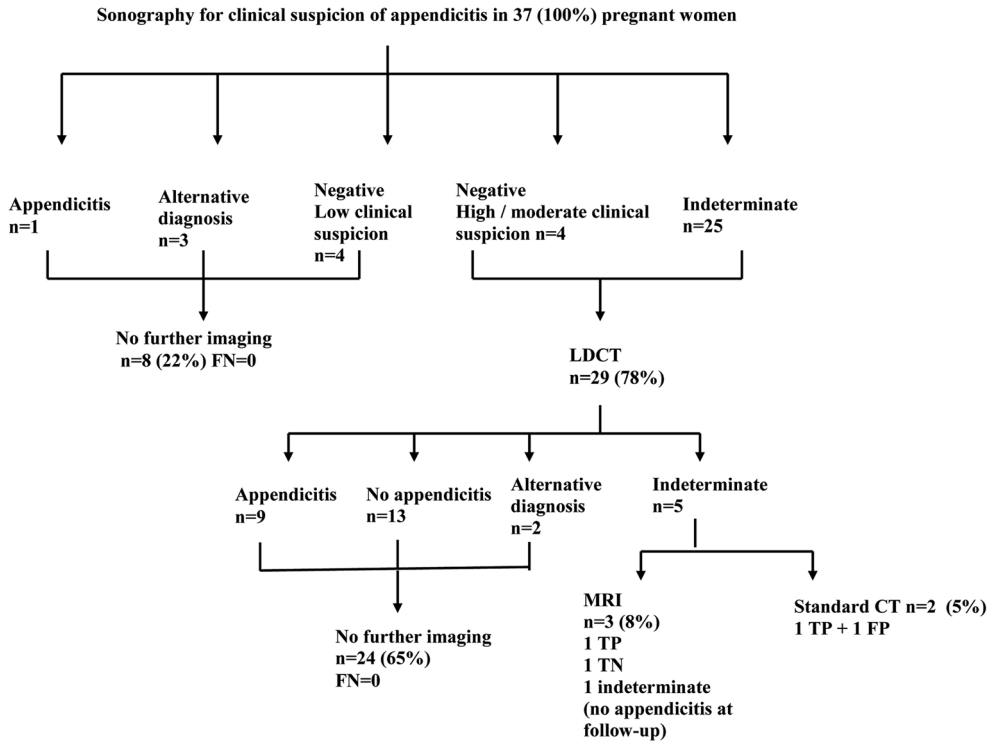

Fig. 1 Imaging algorithm for the diagnosis of appendicitis in pregnant women. *TN* true negative, *TP* true positive, *FN* false negative, *FP* false positive, *LDCT* low-dose CT

trimester) had acute right renal conditions. These three patients were managed without further imaging.

Four of the 11 patients with a negative US (three at second trimester, one at third trimester) had a low clinical suspicion of appendicitis and did not undergo further imaging. The absence of appendicitis was confirmed at clinical follow-up in all of them. The other four patients, of the 11 with a negative US, had a high or moderate clinical suspicion of appendicitis and underwent LDCT. Follow-up showed an alternative diagnosis in two of them (chorioamnionitis, with fetal loss and pyelonephritis) and was uneventful in the two others.

Fig. 2 A 36-year-old pregnant woman (15 weeks), right-lower quadrant pain. Transverse sonography at the level of the right lower quadrant shows the distended appendix (between callipers), surrounded by inflamed hyperechogenic fat (*asterisks*); the examination was reported positive for appendicitis; the diagnosis was confirmed at surgery

US was reported indeterminate in 25 patients (8 at first trimester, 7 at second trimester, 10 at third trimester). Appendicitis was eventually found at follow-up in 11 (44%) of them.

Overall, 8 (22%) of the 37 patients who underwent US did not have further imaging. None of them had a false-negative or false-positive result for appendicitis.

LDCT results

LDCT was performed in 29 (78%) of the 37 patients, who had indeterminate or negative US with high/moderate clinical suspicion of appendicitis. LDCT was conclusive in 24/29 (83%) patients and indeterminate in 5 (17%). Appendicitis was confirmed at surgery in all 9 patients in whom LDCT suggested this diagnosis (Fig. 3). LDCT showed an alternative diagnosis in 2 patients: a ureteral stone (Fig. 4) and a terminal ileitis (Fig. 5).

Further imaging

Five (8%) of the 37 patients (1 at first trimester, 1 at second, 3 at third) of our study population underwent a third-line imaging, after an indeterminate LDCT. An MRI was obtained for three of them and reported one appendicitis (confirmed by surgery) (Fig. 6), one normal case and one indeterminate case for appendicitis respectively. None of these two patients had appendicitis at follow-up.

Standard dose CT was performed in two patients (both at third trimester) and were reported positive for appendicitis. Appendicitis was confirmed at surgery in one of them, while

Fig. 3 A 37-year-old pregnant woman (28 weeks), right lower quadrant pain. Admission US was reported indeterminate for appendicitis. Low-dose CT with oral contrast (axial plane) shows a blind-ended, dilated digestive structure (*arrowheads*), surrounded by fat infiltration (*asterisk*), situated lateral to the caecum (*C*), consistent with an inflamed appendix. Appendicitis was confirmed at surgery

a normal appendix was found in the second one (and confirmed at histopathological analysis).

Statistical analysis of the three-step algorithm

Table 1 shows the results at each imaging step of the algorithm, when compared to the reference standard. By considering the only indeterminate result (without appendicitis at follow-up) as falsely positive for the calculation of the specificity, the overall algorithm was 100% (12/12) sensitive [95% CI (74-100)] and 92% (23/25) specific [95% CI (74-99)], for the diagnosis of appendicitis.

Discussion

Our results show that our algorithm including US and LDCT as first and second imaging steps is highly sensitive and specific for the assessment of pregnant women with a suspicion of appendicitis, and can be used when MRI, the optimal second-line imaging, is not immediately available, to avoid performing a standard-dose CT instead.

In our study population, US was mainly limited by a large number of indeterminate results (94%, 29/37), which contrast with the 49.7 % (91/183) of indeterminate results reported in non-pregnant patients in the same institution [22]. This is consistent with many prior series, reporting between 71 and 98.4% of inconclusive US results for the diagnosis of appendicitis in pregnant women [12–15, 17]. One possible explanation for this high rate of indeterminate results is the progressive upward shift of the appendix with the progression of the pregnancy, which makes it more difficult to be detected [21]. Furthermore, the possibility of performing graded-compression US also decreases as pregnancy progresses [31]. However, these explanations could only concern patients at the third trimester of pregnancy (32% in the current study). A third explanation is that sonologists are more reluctant to assert a positive or negative diagnosis of appendicitis by US in pregnant women because of the potential consequences of a false-negative or false-positive result in this patient population. Indeed, a false-negative result may delay the surgical intervention, with increased risk of fetal loss [32] and a false-positive result will expose the fetus to the well-documented risks associated to anaesthesia and surgical procedures [3, 33].

MRI is usually considered as the second-line imaging after an indeterminate US [7, 19]. In spite of one indeterminate MRI result, the small number of examinations performed in our study with this technique (n = 3) precludes drawing any conclusion about its actual value for assessing appendicitis in pregnant women. However, in this patient category, most of the authors agree that MRI is highly sensitive and specific for appendicitis [34–37] and for depiction of alternative diagnoses [38–40]. A recent study reported that MRI examination could be limited to axial images only [41], which may expedite the procedure.

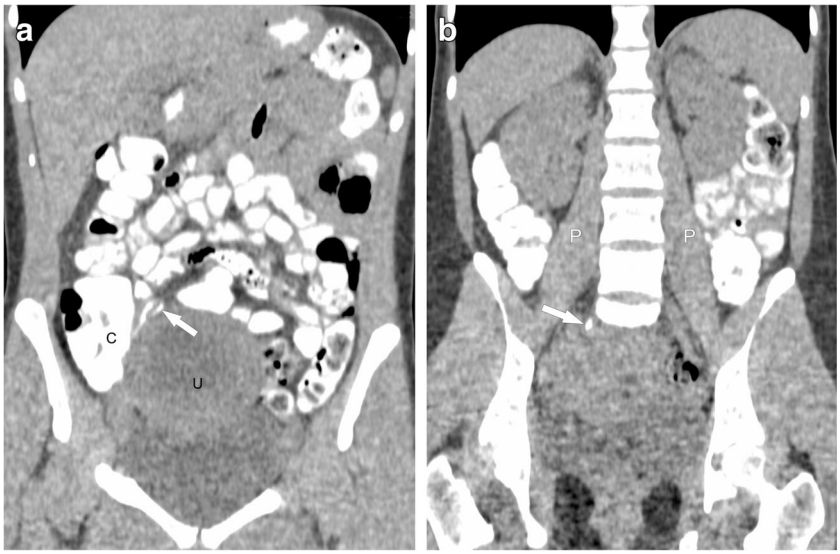

Fig. 4 A 27-year-old pregnant woman (10 weeks), right flank pain. Admission US was reported indeterminate for appendicitis. **a** Low-dose CT with oral contrast (coronal plane) shows a thin, contrast-filled, blind-ending digestive structure (*arrow*), departing from the caecum (*C*), consistent with a normal appendix. The appendix is displaced upwards by the pregnant uterus (*U*). **b** Same patient, coronal reconstruction at the level of the psoas muscles (*P*) shows a urinary stone (*arrow*), at the level of the right lumbar ureter. Low-dose CT was reported positive for right ureteral lithiasis

Fig. 5 A 22-year-old pregnant woman (10 weeks), right lower quadrant pain. Admission US was reported indeterminate for appendicitis. **a** Low-dose CT with oral contrast shows a normal appendix (*arrow*), situated between the caecum (*C*) and the pregnant uterus (*U*). **b** Low-dose CT shows a mild wall thickening of the terminal ileum (*asterisk*) and **c** a cluster of enlarged lymph nodes (*arrowheads*), medial to the caecum (*C*). Images were consistent with primary mesenteric adenitis; patient made an uneventful recovery

Whenever MRI is not available in an emergency setting, CT can be used as second-line imaging [7, 14, 20]. The ESUR guideline states that "if MRI cannot be performed, low-dose CT may be necessary" [7]. However, the ESUR does not provide a recommendation about the LDCT protocol in terms of radiation dose and contrast media. Actually, there is no consensus about the abdominal CT protocol to be used in pregnant women, which raises concern about the radiation dose delivered to the fetus. In a same institution, the dose to the fetus may vary from 4 to 43 mGy (mean,16 mGy) [20].

To our knowledge, no series had assessed the value of LDCT delivering a dose of radiation <2.5 mSv for the assessment of pregnant women with a suspicion of appendicitis. Our study results showed that our LDCT protocol was sufficient to assess or rule out the diagnosis of appendicitis, or of an alternative condition, without need of further imaging in 83% (24/29) of patients who underwent this imaging method without false-negative or false-positive results. These results are consistent with those reported by prior series using CT for the assessment of pregnant women, with higher dose of radiation and administration of i.v. contrast media [14, 20], except that these series did not consider indeterminate results because CT was the reference imaging. In spite of the fact that our LDCT protocol was limited by 17% indeterminate cases, it was sufficient, as a complement to US, to assess the correct diagnosis in 86% (32/37) of patients, in a very brief delay. Indeed, the low-dose of radiation and the absence of i.v. contrast media were an incentive to performing this examination rather than observing the patient over a long period of time.

Further examination (standard dose i.v. CT or MRI) was eventually required in 5 of 37 (14%) patients in whom the diagnosis remained indeterminate after sonography and LDCT. The fact that a correct diagnosis was obtained in only three of these five patients by MRI or CT suggests that the indeterminate cases after US and LDCT correspond to the patients in whom the diagnosis of appendicitis is the most difficult to assess. Overall, the proposed algorithm achieved a 100% sensitivity and a 92% specificity for the assessment of appendicitis in pregnant women, which is comparable to what has been reported for MRI or standard-dose CT [20, 34, 42].

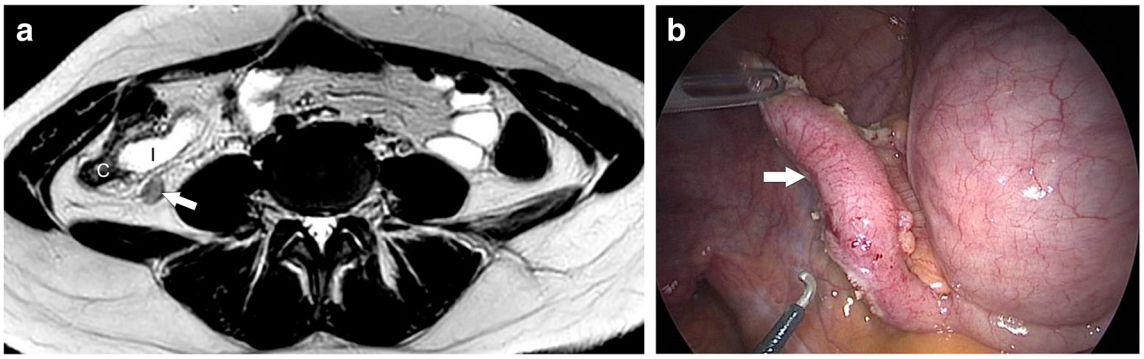

Fig. 6 A 28-year-old pregnant woman (11 weeks), right lower quadrant pain; US and LDCT were reported indeterminate for appendicitis. **a** MR examination (axial T2-weighted sequences) at the level of the pelvis shows the dilated appendix (*arrow*), situated postero-medial to the ileum (*I*) and to the caecum (*C*). MR examination was reported positive for acute appendicitis. **b** Surgical image shows the dilated, inflamed appendix (*arrow*), confirming the pre-operative diagnosis

Table 1 Results obtained by each imaging technique for the diagnostic work-up of right-lower quadrant pain in pregnant women with regard to the reference standard (surgery or follow-up)

	Sonography			Low-dose CT			CT or MRI			All imaging steps		
	Appendicitis*	No Appendicitis*	Total	Appendicitis*	No Appendicitis*	Total	Appendicitis*	No Appendicitis*	Total	Appendicitis*	No Appendicitis*	Total
Positive Imaging	1	0	1	9	0	9	2	1	3	12	1	13
Indeterminate Imaging	11	18	29	2	3	5	0	1	1	0	1	1
Negative Imaging	0	7	7	0	15	15	0	1	**1**	0	23	**23**
Total	12	25	**37**	11	18	**29**	2	3	**5**	12	25	**37**

[a] Based on the reference standard

In addition to its retrospective nature, the current study has some other limitations that should be addressed. The relatively limited number of patients did not allow stratification into the various stages of pregnancy. Therefore, it was not possible to determine how the performance of the algorithm might be influenced by the progression of pregnancy. For the same reason, it was not possible to assess to what extent the rapid availability of both US and LDCT did reduce the morbidity of pregnant patients with appendicitis, when compared to management by US and clinical observation for the triage towards delayed standard i.v. CT or MRI.

In conclusion, our data show that an algorithm based on US and LDCT as first- and second-step imaging in pregnant woman admitted with suspicion of appendicitis can be used to reduce the need for standard CT in acute settings, when MRI is not immediately available.

Acknowledgements Authors wish to thank Gabriel Guglielmi M.D., from the Department of Radiology, University Hospital of Geneva, for his contribution to data collection

Funding The authors state that this work has not received any funding.

Compliance with ethical standards

Guarantor The scientific guarantor of this publication is Prof. Pierre-Alexandre Poletti.

Conflict of interest The authors of this manuscript declare no relationships with any companies, whose products or services may be related to the subject matter of the article.

Statistics and biometry No complex statistical methods were necessary for this paper.

Informed consent Written informed consent was waived by the Institutional Review Board, because of the retrospective nature of the study.

Ethical approval Institutional Review Board approval was obtained.

Methodology
- retrospective
- observational study
- performed at one institution

References

1. Gilo NB, Amini D, Landy HJ (2009) Appendicitis and cholecystitis in pregnancy. Clin Obstet Gynecol 52:586–596
2. Cappell MS, Friedel D (2003) Abdominal pain during pregnancy. Gastroenterol Clin North Am 32:1–58
3. Long SS, Long C, Lai H, Macura KJ (2011) Imaging strategies for right lower quadrant pain in pregnancy. AJR Am J Roentgenol 196:4–12
4. Segev L, Segev Y, Rayman S, Nissan A, Sadot E (2017) Acute appendicitis during pregnancy: different from the nonpregnant state? World J Surg 41:75–81
5. Sharp HT (2002) The acute abdomen during pregnancy. Clin Obstet Gynecol 45:405–413
6. Bickell NA, Aufses AH Jr, Rojas M, Bodian C (2006) How time affects the risk of rupture in appendicitis. J Am Coll Surg 202:401–406
7. Masselli G, Derchi L, McHugo J et al (2013) Acute abdominal and pelvic pain in pregnancy: ESUR recommendations. Eur Radiol 23: 3485–3500
8. Glanc P, Maxwell C (2010) Acute abdomen in pregnancy: role of sonography. J Ultrasound Med 29:1457–1468
9. Khandelwal A, Fasih N, Kielar A (2013) Imaging of acute abdomen in pregnancy. Radiol Clin North Am 51:1005–1022
10. Masselli G, Brunelli R, Monti R et al (2014) Imaging for acute pelvic pain in pregnancy. Insights Imaging 5:165–181
11. Segev L, Segev Y, Rayman S, Nissan A, Sadot E (2016) The diagnostic performance of ultrasound for acute appendicitis in pregnant and young nonpregnant women: a case-control study. Int J Surg 34: 81–85
12. Lehnert BE, Gross JA, Linnau KF, Moshiri M (2012) Utility of ultrasound for evaluating the appendix during the second and third trimester of pregnancy. Emerg Radiol 19:293–299
13. Pedrosa I, Lafornara M, Pandharipande PV, Goldsmith JD, Rofsky NM (2009) Pregnant patients suspected of having acute appendicitis: effect of MR imaging on negative laparotomy rate and appendiceal perforation rate. Radiology 250:749–757
14. Wallace CA, Petrov MS, Soybel DI, Ferzoco SJ, Ashley SW, Tavakkolizadeh A (2008) Influence of imaging on the negative appendectomy rate in pregnancy. J Gastrointest Surg 12:46–50
15. Shetty MK, Garrett NM, Carpenter WS, Shah YP, Roberts C (2010) Abdominal computed tomography during pregnancy for suspected appendicitis: a 5-year experience at a maternity hospital. Semin Ultrasound CT MR 31:8–13
16. Freeland M, King E, Safcsak K, Durham R (2009) Diagnosis of appendicitis in pregnancy. Am J Surg 198:753–758
17. Ramalingam V, LeBedis C, Kelly JR, Uyeda J, Soto JA, Anderson SW (2015) Evaluation of a sequential multi-modality imaging algorithm for the diagnosis of acute appendicitis in the pregnant female. Emerg Radiol 22:125–132

18. Wieseler KM, Bhargava P, Kanal KM, Vaidya S, Stewart BK, Dighe MK (2010) Imaging in pregnant patients: examination appropriateness. Radiographics 30:1215–1229 discussion 1230-1213
19. Smith MP, Katz DS, Lalani T et al (2015) ACR appropriateness Criteria® right lower quadrant pain—suspected appendicitis. Ultrasound Q 31:85–91
20. Lazarus E, Mayo-Smith WW, Mainiero MB, Spencer PK (2007) CT in the evaluation of nontraumatic abdominal pain in pregnant women. Radiology 244:784–790
21. Wang PI, Chong ST, Kielar AZ et al (2012) Imaging of pregnant and lactating patients: part 1, evidence-based review and recommendations. AJR Am J Roentgenol 198:778–784
22. Poletti PA, Platon A, De Perrot T et al (2011) Acute appendicitis: prospective evaluation of a diagnostic algorithm integrating ultrasound and low-dose CT to reduce the need of standard CT. Eur Radiol 21:2558–2566
23. Funaki B, Grosskreutz SR, Funaki CN (1998) Using unenhanced helical CT with enteric contrast material for suspected appendicitis in patients treated at a community hospital. AJR Am J Roentgenol 171:997–1001
24. Trottier M, Erebara A, Bozzo P (2012) Treating constipation during pregnancy. Can Fam Physician 58:836–838
25. Huda W, Ogden KM, Khorasani MR (2008) Converting dose-length product to effective dose at CT. Radiology 248:995–1003
26. Millon D, Vlassenbroek A, Van Maanen AG, Cambier SE, Coche EE (2017) Low contrast detectability and spatial resolution with model-based Iterative reconstructions of MDCT images: a phantom and cadaveric study. Eur Radiol 27:927–937
27. Hara AK, Paden RG, Silva AC, Kujak JL, Lawder HJ, Pavlicek W (2009) Iterative reconstruction technique for reducing body radiation dose at CT: feasibility study. AJR Am J Roentgenol 193:764–771
28. Radimetrics™ Radimetrics™ Enterprise Platform: dose management solution. Available via https://www.radiologysolutions.bayer.com/products/ct/dosemanage. Accessed 19 December 2017
29. Xie T, Poletti PA, Platon A, Becker CD, Zaidi H (2018) Assessment of CT dose to the fetus and pregnant female patient using patient-specific computational models. Eur Radiol 28:1054-1065
30. Huda W, Ogden KM, Khorasani MR (2008) Converting dose-length product to effective dose at CT 1. Radiology 248:995–1003
31. Pedrosa I, Levine D, Eyvazzadeh AD, Siewert B, Ngo L, Rofsky NM (2006) MR imaging evaluation of acute appendicitis in pregnancy. Radiology 238:891–899
32. Abbasi N, Patenaude V, Abenhaim HA (2014) Management and outcomes of acute appendicitis in pregnancy-population-based study of over 7000 cases. BJOG 121:1509–1514
33. McGory ML, Zingmond DS, Tillou A, Hiatt JR, Ko CY, Cryer HM (2007) Negative appendectomy in pregnant women is associated with a substantial risk of fetal loss. J Am Coll Surg 205:534–540
34. Duke E, Kalb B, Arif-Tiwari H et al (2016) A systematic review and meta-analysis of diagnostic performance of MRI for evaluation of acute appendicitis. AJR Am J Roentgenol 206:508–517
35. Burke LM, Bashir MR, Miller FH et al (2015) Magnetic resonance imaging of acute appendicitis in pregnancy: a 5-year multiinstitutional study. Am J Obstet Gynecol 213:693 e691–693 e696
36. Patel D, Fingard J, Winters S, Low G (2017) Clinical use of MRI for the evaluation of acute appendicitis during pregnancy. Abdom Radiol (NY) 42:1857–1863
37. Shin I, An C, Lim JS, Kim MJ, Chung YE (2017) T1 bright appendix sign to exclude acute appendicitis in pregnant women. Eur Radiol 27:3310–3316
38. Heverhagen JT, Pfestroff K, Heverhagen AE, Klose KJ, Kessler K, Sitter H (2012) Diagnostic accuracy of magnetic resonance imaging: a prospective evaluation of patients with suspected appendicitis (diamond). J Magn Reson Imaging 35:617–623
39. Theilen LH, Mellnick VM, Longman RE et al (2015) Utility of magnetic resonance imaging for suspected appendicitis in pregnant women. Am J Obstet Gynecol 212(345):e341–e346
40. Cobben LP, Groot I, Haans L, Blickman JG, Puylaert J (2004) MRI for clinically suspected appendicitis during pregnancy. AJR Am J Roentgenol 183:671–675
41. Shin I, Chung YE, An C et al (2018) Optimisation of the MR protocol in pregnant women with suspected acute appendicitis. Eur Radiol 28:514–521
42. Basaran A, Basaran M (2009) Diagnosis of acute appendicitis during pregnancy: a systematic review. Obstet Gynecol Surv 64:481–488 quiz 499